



LETTER TO THE EDITOR

The familial cerebral cavernous malformation presented with facial paralysis

Ezgi Erogul^{ID}, Rabia Gokcen Gozubatik Celik^{ID}, Isil Yazici Gencdal^{ID}, Tugba Argun Pulat^{ID},
Banu Bayramoglu^{ID}, Ayten Ceyhan Dirican^{ID}, Belgin Mutluay^{ID}, Aysu Sen^{ID}

Bakirkoy Prof. Mazhar Osman Training and Research Hospital for Psychiatry, Neurology, and Neurosurgery, Department of Neurology, Istanbul, Turkiye

Dear Editor,

Cerebral cavernous malformations (CCMs) are common vascular anomalies of the central nervous system, consisting of clustered and enlarged channels known as cavernomas, each surrounded by a single endothelial layer (1). The familial form, which exhibits autosomal dominant inheritance, is rare. These malformations often present with seizures or focal neurological symptoms, although many cases may remain asymptomatic for years. Nonetheless, acute hemorrhages from cavernomas can occur over time. Three genes have been identified as causing mutations in familial cerebral cavernous malformations: KRIT-1 (CCM-1), CCM-2, and PDCD-10 (CCM-3) (2).

We report a case of a patient who presented with intranuclear facial paralysis and was subsequently diagnosed with familial cerebral cavernous malformation.

A 23-year-old male presented to the emergency department with a new onset of severe headache. The headache was bilateral, compressive, not accompanied by nausea and vomiting, and significantly more severe than any previous headaches the patient had experienced. The patient had no known history of any other diseases, and his regular medication intake, as well as consumption of cigarettes and alcohol, were unremarkable. He

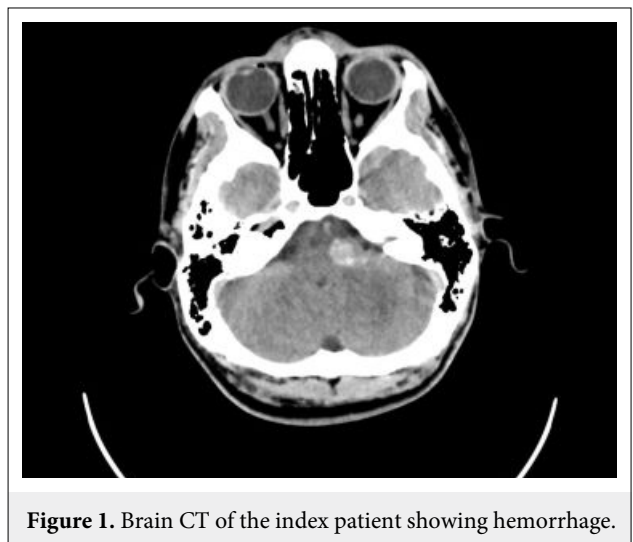


Figure 1. Brain CT of the index patient showing hemorrhage.

reported that his father had hypertension and Immunoglobulin A (IgA) nephropathy. On the third day following the onset of his headache, the patient developed new symptoms, including numbness on the left half of his face and an inability to close his left eyelid. After being diagnosed with peripheral facial paralysis, oral steroid treatment was initiated. His vital signs and blood test results were normal. However, a brain computed tomography (CT) scan detected a left pontocerebellar peduncle hemorrhage (Fig. 1), and brain Magnetic Resonance Imaging (MRI)

How to cite this article: Erogul E, Gozubatik Celik RG, Yazici Gencdal I, Argun Pulat T, Bayramoglu B, Ceyhan Dirican A, Mutluay B, Sen A. The familial cerebral cavernous malformation presented with facial paralysis. *Dusunen Adam J Psychiatr Neurol Sci* 2024;37:54-56.

Correspondence: Ezgi Erogul, Bakirkoy Prof. Mazhar Osman Training and Research Hospital for Psychiatry, Neurology, and Neurosurgery, Department of Neurology, Istanbul, Turkiye

E-mail: ezgierogul95@gmail.com

Received: April 27, 2023; **Revised:** January 07, 2024; **Accepted:** January 12, 2024

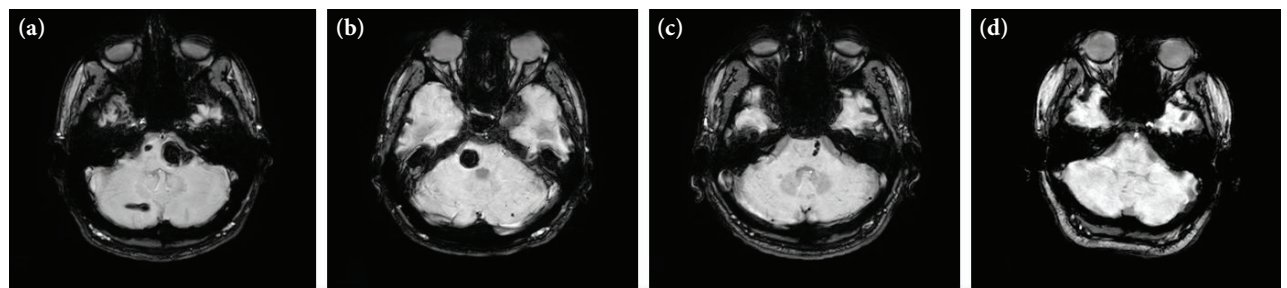


Figure 2. Axial brainstem imaging. (a) Index patient's SWI sequence MRI. (b) Patient's brother's SWI sequence MRI. (c) Patient's father's SWI sequence MRI. (d) Patient's mother's normal MRI.

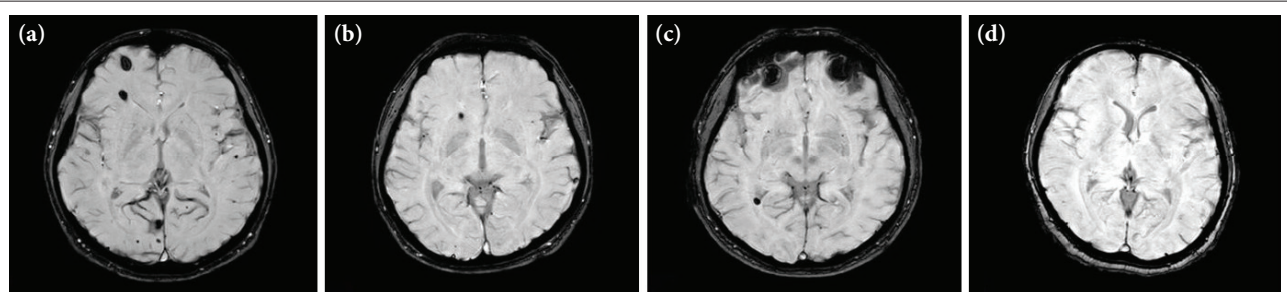


Figure 3. Axial hemispheric imaging. (a) Index patient's SWI sequence MRI. (b) Patient's brother's SWI sequence MRI. (c) Patient's father's SWI sequence MRI. (d) Patient's mother's normal MRI.

revealed innumerable lesions of decreased signal intensity on T1- and T2-weighted images, as well as on susceptibility-weighted imaging (SWI). These lesions were observed throughout both the right and left cerebral hemispheres, as well as on the brainstem and cerebellum. The lesions were identified as multiple cavernomas. Given the presence of multiple lesions in a young patient, a familial etiology was explored. With a preliminary diagnosis of familial CCM, brain imaging was conducted on both parents and the brother of the patient, none of whom presented with any similar clinical symptoms. The father's MRI revealed a hypointense lesion on the lateral part of the left pons and adjacent to the posterior horn of the left lateral ventricle, as observed on the SWI sequence. The older brother's MRI showed a hypointense cavernoma in the right pontocerebellar region on the SWI sequence, while, surprisingly, the mother's neuroimaging was normal (Fig. 2 and Fig. 3). Both our patient and his asymptomatic brother underwent gamma knife surgery.

In young individuals, underlying secondary causes of facial paralysis are rare. Nuclear-level causes should be considered in patients presenting with facial paralysis. Intracerebral hemorrhages are among the secondary etiologies in young patients. In cases of abnormal

localized cerebrocerebellar hemorrhages, underlying vascular malformations should be investigated. The SWI sequence, in particular, plays a crucial role in detecting cavernomas. The presence of multiple lesions on cerebral magnetic resonance imaging suggests the familial form of the disease, with 20-50% of affected individuals developing symptoms between the second and fifth decades of life (1). Therefore, precautions are necessary for patients without clinical symptoms. The coexistence of cavernous malformations and developmental venous anomalies occurs in approximately 33% of cases. Skin (9%), retina (5%), and liver lesions have been reported, albeit rarely (1). There were no findings suggestive of any venous anomaly in our patient's abdominal ultrasonography and body inspection, and his eye exam was normal.

This case highlights the early diagnosis of two asymptomatic cases of familial cavernomas, emphasizing that treatment is possible even in the absence of vital symptoms. In asymptomatic patients, MRI follow-up can be conducted, taking into account the cavernoma's location and additional risk factors. However, studies have indicated that radiosurgery, by reducing the risk of future bleeding, can also be considered for asymptomatic patients after evaluating the risks (3).

We wish to underscore the importance of scanning family members of a patient with multiple cavernomas detected on neuroimaging (4). SWI imaging is deemed essential in patients presenting with intracranial hemorrhage (5). Genetic counseling could be beneficial in assessing the risk for future generations. Due to technical limitations, the genes associated with familial cerebral cavernous malformation in our patient and other affected family members could not be analyzed. Therefore, we acknowledge this as a limitation.

Through this case, we aim to underline that lesions in the facial nerve nucleus may manifest as peripheral facial palsy and that further investigation is needed to diagnose intracranial etiologies. The presence of multiple cerebral cavernous lesions suggests a familial etiology; therefore, it is advantageous to scan family members to initiate treatment before symptoms develop.

Conflict of Interest: The authors declare that they have no conflict of interest.

Informed Consent: We confirm that written informed consent for the publication of their case was obtained from the patients.

Use of AI for Writing Assistance: Not declared.

Financial Disclosure: The authors declare that they have no financial support.

Peer-review: Externally peer-reviewed.

REFERENCES

1. Mespreuve M, Vanhoenacker F, Lemmerling M. Familial multiple cavernous malformation syndrome: MR features in this uncommon but silent threat. *J Belg Soc Radiol* 2016; 100:51.
2. Snellings DA, Hong CC, Ren AA, Lopez-Ramirez MA, Girard R, Srinath A, et al. Cerebral cavernous malformation: from mechanism to therapy. *Circ Res* 2021; 129:195-215. Erratum in: *Circ Res* 2021; 129:e101. [[CrossRef](#)]
3. Ganz JC. Cavernous malformations. *Prog Brain Res* 2022; 268:115-132. [[CrossRef](#)]
4. Nicholas-Bublick S, Koffman BM. Varying clinical presentations of familial cerebral cavernous malformations (CCMs) and spinal cord cavernous malformations (SCCMs). *Radiol Case Rep* 2015; 7:678. [[CrossRef](#)]
5. de Souza JM, Domingues RC, Cruz LC Jr, Domingues FS, Iasbeck T, Gasparetto EL. Susceptibility-weighted imaging for the evaluation of patients with familial cerebral cavernous malformations: a comparison with t2-weighted fast spin-echo and gradient-echo sequences. *AJNR Am J Neuroradiol* 2008; 29:154-158. [[CrossRef](#)]