

# Isolated Axillary Nerve Involvement: A Case Report

Betul Tekin Guveli<sup>1</sup>, Fikret Aysal<sup>2</sup>,  
Azize Esra Gursoy<sup>3</sup>,  
Mehmet Kolukisa<sup>3</sup>, Suna Askin<sup>4</sup>,  
Ahmet Hakyemez<sup>5</sup>, Arif Celebi<sup>3</sup>

<sup>1</sup>Neurologist, Bakirkoy Training and Research Hospital for Psychiatry Neurology and Neurosurgery,  
<sup>1st</sup> Department of Neurology, Istanbul - Turkey

<sup>2</sup>Neurologist, Bakirkoy Training and Research Hospital for Psychiatry Neurology and Neurosurgery,  
<sup>2nd</sup> Department of Neurology, Istanbul - Turkey

<sup>3</sup>Neurologist, Bezmialem Vakif University, Faculty of Medicine, Department of Neurology, Istanbul - Turkey

<sup>4</sup>Neurologist, Okmeydani Training and Research Hospital, Department of Neurology, Istanbul - Turkey

<sup>5</sup>Neurologist, Istanbul Training and Research Hospital, Department of Neurology, Istanbul - Turkey

## ABSTRACT

### Isolated axillary nerve involvement: a case report

Isolated axillary neuropathy is a rare condition. Trauma to the shoulder, especially dislocation of the shoulder is the most common cause. The other causes of axillary neuropathy are injection to the shoulder, carrying heavy backpacks and acute idiopathic brachial plexus neuropathy. Differential diagnosis should be made especially between cervical 5-6 radiculopathy and upper truncus brachial plexopathy.

**Case:** A 32-year-old man admitted with progressive atrophy and weakness of the right shoulder which developed after deep pain. In his neurological examination, abduction weakness and atrophy of the right shoulder was determined. Magnetic resonance imaging findings of cervical spine and right shoulder were normal. Electrophysiologic examination revealed reduced compound muscle action potential amplitude of the right axillary nerve, recorded from deltoid muscle, compared to the left side. On needle EMG, subacute neurogenic signs in the right deltoid and teres minor muscles which are innervated by the axillary nerve were detected. Etiological evaluation revealed no cause. It has been suggested that isolated axillary neuropathy may be associated with Personage-Turner syndrome. Antiinflammatory medications and physical therapy provided partial improvement. The aim of our presentation was to discuss the differential diagnosis, treatment options and etiologic causes of axillary neuropathy.

**Key words:** Axillary nerve, acute idiopathic brachial plexus neuropathy, EMG



## ÖZET

### İzole aksiller sinir tutulumu: Olgu sunumu

İzole aksiller sinir tutulumu nadir görülen bir durumdur. En sık karşılaşılan neden omuz travması, özellikle omuz çıkığıdır. Omuza yapılan enjeksiyon, sırt çantası kullanımı veya akut idiyopatik brakial pleksus nöropatisi diğer etiyolojik nedenler olabilir. C5/C6 radikülopati, brakial pleksus üst trunkus tutulumu ile ayırıcı tanısı yapılmalıdır.

**Olgu:** Sağ omuzda şiddetli ağrı sonrası güçsüzlük ve incelme gelişen, nörolojik muayenede sağ omuz abduksiyon zaaf ve atrofisi olan 32 yaşındaki erkek hastanın servikal spinal ve omuz MR incelemeleri normaldi. Elektrofizyolojik incelemede, sağ aksiller sinir bileşik kas aksiyon potansiyeli, deltoid kasından kayıtlama ile sola göre düşüktü. İğne elektromiyografisinde aksiller sinir inervasyonlu deltoid ve teres minör kaslarında subakut dönem nörojenik tutulum bulguları saptandı. Etiyolojik araştırmada neden bulunamadı. İzole aksiller sinir tutulumunun Personage-Turner Sendromuna bağlı olabileceği düşünüldü. Antienflamatuvar ilaçlar ve fizik tedavi ile hasta kısmen düzeldi. Vaka; ayırıcı tanı, tedavi ve etiyolojik nedenleri tartışmak amacı ile sunuldu.

**Anahtar kelimeler:** Aksiller sinir, akut idiyopatik brakial pleksus nöropatisi, EMG

Address reprint requests to / Yazışma adresi:  
Neurologist Betül Tekin Guveli, Bakirkoy  
Training and Research Hospital for Psychiatry  
Neurology and Neurosurgery, 1<sup>st</sup> Department  
of Neurology, Istanbul - Turkey

Phone / Telefon: +90-212-543-6565

E-mail address / Elektronik posta adresi:  
betultekin2013@gmail.com

Date of receipt / Geliş tarihi:  
February 27, 2012 / 27 Şubat 2012

Date of acceptance / Kabul tarihi:  
April 24, 2012 / 24 Nisan 2012

## INTRODUCTION

The axillary nerve is comprised of fibers from the C5-C6 cervical nerve roots. It leaves upper truncus and posterior cord of brachial plexus. Axillary nerve first extends from the lateral side of the radial nerve, then

passes laterally and posteriorly, and located under the shoulder joint. Then it travels through the quadrangular space formed by neck of the humerus, long head of the triceps, teres minor and teres major muscles. It divides into anterior and posterior branches in the deltoid muscle. While its motor fibers innervate the deltoid and

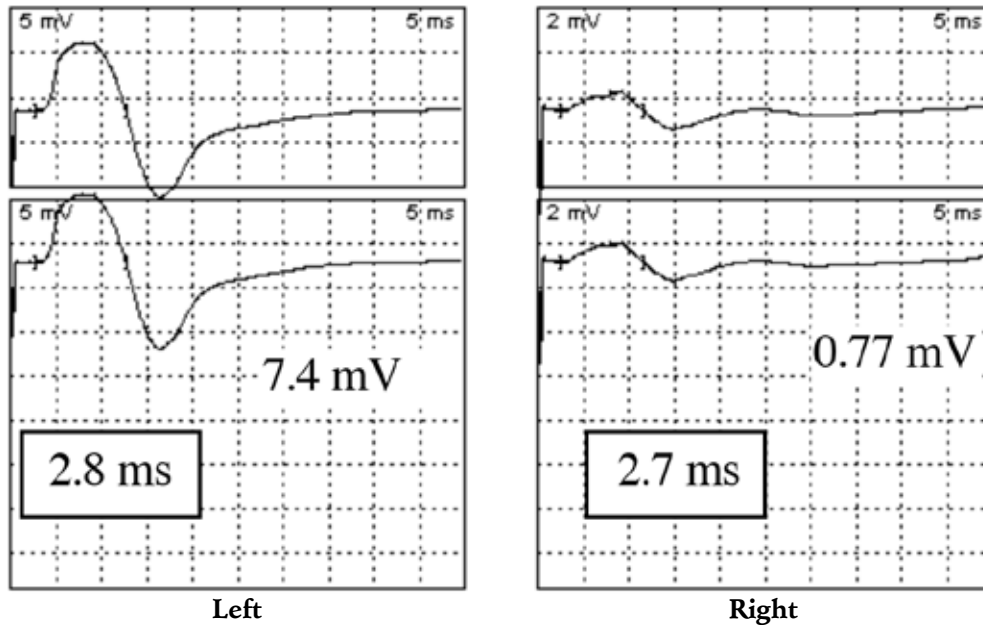


Figure 1: Axillary nerve motor conduction study. (Stimulation: Erb. Record: Deltoid muscle)

Table 1: Other motor nerve conduction studies

	Latance(ms)	Amp(mV)	C.V.(m/s)
<b>Right median nerve</b>			
Recording: APB			
Stimulation			
Wrist	3.8	8.8	
Antecubital fossa	8.6	8.4	56.3
<b>Right ulnar nerve</b>			
Recording: ADM			
Stimulation			
Wrist	3.1	11.1	
Below elbow	8.2	10.3	51.0
Above elbow	10.6	9.6	50.7

(ADM: Abductor digiti minimi muscle, APB: Abductor pollicis brevis muscle, Amp: Amplitude, mV: milivolt, ms: milisecond, CV: conduction velocity, m/s: meter/second)

Table 2: Sensory nerve conduction studies

	Peak latance (ms)	Amp (µV)	C.V.(m/s)
<b>Right median nerve</b>			
Recording: Wrist			
Stimulation			
1. palm	3.4	26.6	
3. palm	3.6	29.6	
2. palm	3.6	30.6	50.0
<b>Right ulnar nerve</b>			
Recording:Wrist			
Stimulation			
5. palm	3.4	15.3	48.5

(Amp: Amplitude, ms: milisecond, µV: mikrovolt, C.V.: conduction velocity, m/s: meter/second)

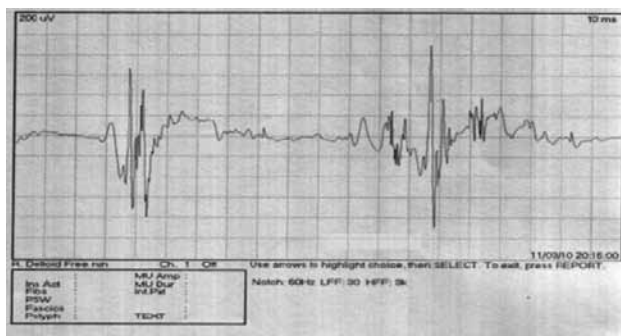
teres minor muscles, its sensory fibers carry sensory information from the shoulder joint, as well as the skin covering the inferior region of the deltoid muscle (1). Isolated axillary nerve involvement generally appears secondary to the trauma and reveals itself through limitation of the shoulder movements (2).

### CASE

It has come to the knowledge that a 32 year old male patient has referred to a physical therapy rehabilitation

clinic due to severe right shoulder pain. He could not recall a specific precipitating traumatic event. The cervical spinal and the shoulder MR findings were normal and he has been treated with with anti-inflammatory drugs. It was determined that the pain complaints lessened, however there was weakness and slimming on the shoulder. Neurological examination revealed muscle strength (Medical Research Council scale) as 3 in shoulder abduction, atrophy of deltoid muscle and hypoesthesia in the area of axillar nerve sensory distribution.

At the sixth month of the disease onset, nerve



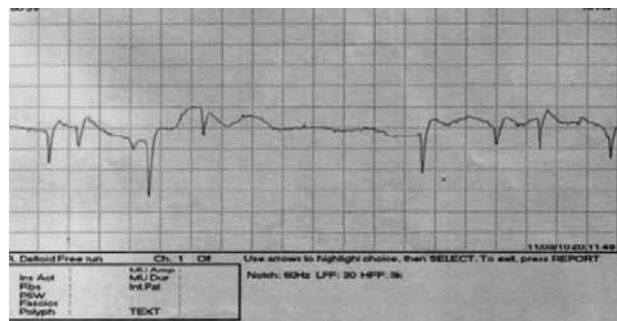
**Figure 2: Reinnervation potentials in the right deltoid muscle**

conduction study (NCS) performed by surface stimulation along the posterior border of the sternocleidomastoid muscle and recording from the deltoid muscle, revealed that right axillary nerve compound muscle action potential amplitude was lower compared to the left side (Figure 1). NCSs of the other motor and sensorial nerves showed normal results (Table 1,2).

Needle electromyography (EMG) studies revealed reduced recruitment of polyphasic motor unit potentials, with prolonged duration and normal and increased amplitude in the right deltoid and teres minor muscles (Figure 2), with resting fibrillation potentials and positive sharp waves in deltoid muscle (Figure 3). EMG findings regarding the right teres major, biceps, brachioradial, supraspinatus, infraspinatus, rhomboideus major, serratus anterior, triceps, flexor carpi radialis, extensor digitorum communis, first dorsal interosseus were all within the normal limits.

## DISCUSSION

The reason of the diagnostic delay of our presenting case might be that the isolated axillary nerve involvement is a rarely encountered condition. Because of the low amplitude of right axillary nerve CMAP, an axonal damage was taken into consideration. Normal findings of median nerve sensory conduction study from the first finger and the lateral cutaneous nerve of the forearm conduction study suggested that lesion might be localized to anterior root or anterior horn. Normal needle EMG findings of the muscles innervated from



**Figure 3: Denervation potentials in right deltoid muscle**

the C5-C6 cervical nerve roots except teres minor and deltoideus muscle confirmed the diagnosis of the isolated axillary nerve involvement.

We evaluated ANA, ds DNA, anticardiolipin antibodies, brucella, syphilis and tumour markers including CEA, AFP, PSA, CA-125 for differential diagnosis of vasculitis, because it is well known that vasculitic neuropathy could manifest with an isolated nerve involvement at disease onset and later with mononeuritis multiplex.

Isolated axillary nerve involvement is a rare condition. Injury to the axillary nerve is most commonly reported following trauma of the shoulder. Visser et al. (3) reported axillary nerve involvement in anterior shoulder dislocations as common as 42%. Various causes including deep intramuscular injection in the deltoid muscle, carrying heavy backpacks and long duration of general anesthesia at a position have also been described (1). Our patient could not recall a specific precipitating traumatic event. We excluded primary shoulder disorders including rotator cuff injuries and calcified tendinitis and cervical spinal disorders including spondylosis and cervical discopathy with normal findings on MR examination. We established the diagnosis isolated axillary neuropathy as a manifestation of idiopathic acute brachial plexus neuropathy.

Acute brachial plexus neuropathy was described for the first time in the 1940s and there are synonyms such as "Parsonage-Turner syndrome, neuralgic amyotrophy, and acute brachial neuralgia". It is usually sporadic but recently SEPT9 gene mutations have been identified in

hereditary form, which is inherited as an autosomal dominant trait and has an episodic course (1). It may be seen in all age groups and more common in males (3:2). Its incidence reported annually 2-3/100 000 (1). Its etiology is unknown, but viral infections, vaccinations and immunologic causes may be responsible. It is characterized by severe shoulder pain at night which is followed by weakness and atrophy of at least one shoulder muscle in a few weeks. "Lasegue sign of the arm" is called increasing of pain with compression or movement of the affected shoulder. Paresthesia, hypoesthesia, and rarely allodynia may occur at the beginning of attacks. Autonomic disorders may be accompanied by vegetative or trophic skin changes, edema, temperature regulation disorders, increased sweating (4,5). The long thoracic nerve affected most commonly. Suprascapular and axillary nerve involvement is usually together with multiple nerve involvement. Isolated axillary nerve involvement reported in 10% cases (2,6).

Acute brachial plexus neuropathy should be diagnosed, after the exclusion of all other causes which may cause shoulder pain and weakness. Its recurrence is rare and prognosis is good (4,7). Treatment of acute brachial plexus neuropathy is usually anti-inflammatory drugs and physiotherapy. Tsairis et al. (8) reported, that 99 patients with neuralgic amyotrophy who improved after 2 years 80% and 3 years 90% of them.

In conclusion, idiopathic axillary nerve palsy is an infrequent neuromuscular disorder. The diagnostic evaluation of idiopathic axillary nerve palsy should be based on history and physical findings and confirmed by electromyography. In the differential diagnosis of the isolated axillary nerve palsy the diagnosis of acute brachial plexus neuropathy should be kept in mind especially in patients with painful onset and development of weakness and atrophy in weeks. The preferred treatment is conservative, with analgesia and physiotherapy as the primary treatment methods with a relatively good outcome.

## REFERENCES

1. Stewart JD. Focal Peripheral Neuropathies. Canada: JBJ Publishing, 2010, 173-177.
2. Bonnard C, Anastakis DJ, van Melle G, Narakas AO. Isolated and combined lesions of the axillary nerve a review of 146 cases. *J Bone Joint Surg Br* 1999; 81:212-217.
3. Visser CP, Coene LN, Brand R, Tavy DL. The incidence of nerve injury in anterior dislocation of the shoulder and its influence on functional recovery. *J Bone Joint Surg Br* 1999; 81:679-685.
4. Favero KJ, Hawkins RH, Jones MW. Neuralgic amyotrophy. *J Bone Joint Surg Br* 1987; 69:195-198.
5. Misomare GW, Lehman DE. Parsonage-Turner Syndrome (acute brachial neuritis). *J Bone Joint Surg Am* 1996; 78:1405-1408.
6. Goslin KL, Krivickas LS. Proximal neuropathies of the upper extremity. *Neurol Clin* 1999; 17:525-545.
7. van Alfen N, van Engelen BG. The clinical spectrum of neuralgic amyotrophy in 246 cases. *Brain* 2006; 129:438-450.
8. Tsairis P, Dyck PJ, Mulder DW. Natural history of brachial plexus neuropathy. Report on 99 patients. *Arch Neurol* 1972; 27:109-117.