

# Concomitant Heart and Brain Hydatid Cyst without Other Organ Involvement: A Case Report

Mehmet Ali Ekici<sup>1</sup>, Arzu Ekici<sup>2</sup>,  
Hüseyin Per<sup>3</sup>, Bülent Tucer<sup>4</sup>,  
Sefer Kumandaş<sup>3</sup>, Ali Kurtsoy<sup>5</sup>

<sup>1</sup>Asist. Prof. Dr., Bozok University, Medical School, Department of Neurosurgery, Yozgat - Turkey  
<sup>2</sup>Neurologist, Osmangazi University, Medical School, Department of Pediatric Neurology, Eskişehir - Turkey  
<sup>3</sup>Prof. Dr., Erciyes University, Medical School, Department of Pediatric Neurology, Kayseri - Turkey  
<sup>4</sup>Assoc. Prof. Dr., <sup>5</sup>Prof. Dr., Erciyes University, Medical School, Department of Neurosurgery, Kayseri - Turkey

## ABSTRACT

Concomitant heart and brain hydatid cyst without other organ involvement: a case report

The tapeworm *Echinococcus granulosus* can cause parasitic disease in the human body. The definitive host for the adult form is usually dog, in the intestine of which tapeworm lives in large numbers. Hydatid cyst is caused by water and food polluted with parasites' larva, or direct contact with dogs. Humans can rarely become intermediate hosts when they are infected by ingesting contaminated food, or by contact with infected animals. We report a pediatric case with cerebral and cardiac involvement. The patient had been operated with the diagnosis of primary multiple cyst hydatid disease one year before. Cysts were delivered by the Downing technique at the operation without rupture, but they relapsed in the same area. The first origin was investigated by thorax-abdominal computed tomography, echocardiography, abdominal ultrasonography. The focus of the cyst was found in the left atrium. This report has been written to stress concomitant brain and cardiac involvement of hydatid cyst disease.

**Key words:** Hydatid cyst, echinococcus granulosus, negative serologies

## ÖZET

Diğer organların tutulumu olmaksızın eş zamanlı kalp ve beyin kist hidatik tutulumu: Olgu bildirim

*Echinococcus granulosus*'un şerit formu insan vücudunda parazitik enfeksiyona sebep olabilir. Erişkin form için son konak sıklıkla köpekler olup, şerit form köpeklerin sindirim sisteminde yaşar. Kist hidatiğin insana bulaşması köpeklerle direkt temasta ya da parazitin larvalarıyla kirlenmiş su ve yiyecekler yüzündendir. Enfekte hayvanlarla temas veya kontamine yiyeceklerin vücuda alınmasıyla insanlar nadiren ara konak olabilir. Bu makalede serebral ve kardiyak kistleri olan pediatrik bir olgu sunulmuştur. Olgu bir yıl önce primer kist hidatik tanısıyla opere edilmiştir. Kistler Downing tekniği ile rüptüre edilmeden doğurtulmasına rağmen aynı bölgede tekrarlamıştır. Bilgisayarlı tomografi, ekokardiyografi ve abdominal ultrasonografi incelemeleri sonrasında ilk odağın kalp sol atriumunda olduğu tespit edilmiştir. Bu rapor, eş zamanlı beyin ve kalp tutulumuna vurgu yapmak için yazılmıştır.

**Anahtar kelimeler:** Kist hidatik, *Echinococcus granulosus*, negatif seroloji

Address reprint requests to:  
Asist. Prof. Dr., Mehmet Ali Ekici, Bozok University, Medical School, Department of Neurosurgery, Yozgat - Turkey

Phone: +90-354-212-6201

Fax: +90-354-214-0612

E-mail address:  
mehmetali.ekici@gmail.com

Date of receipt:  
September 26, 2010

Date of acceptance:  
January 08, 2011

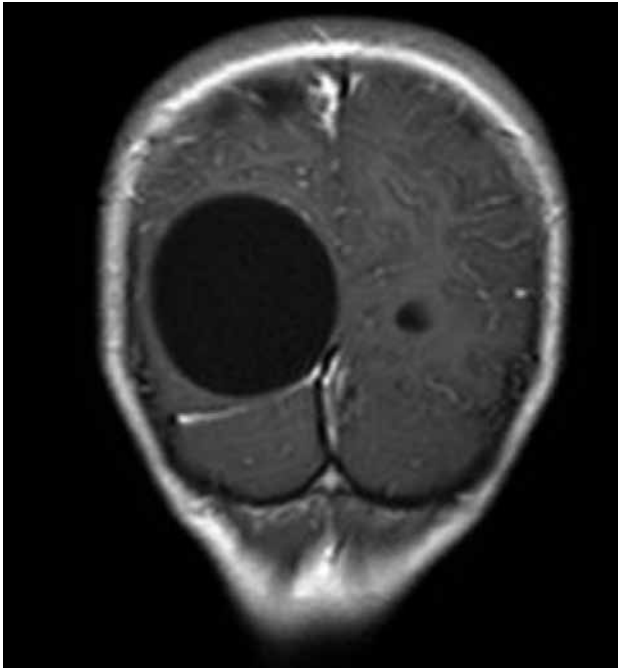
## INTRODUCTION

*Echinococcus granulosus* can cause echinococcosis, a parasitic disease, in the human body. The definitive host for the adult form is usually the dog, in the intestine of which the tapeworm lives in large numbers. Hydatid cyst disease results from water and food polluted with parasite larva, or direct contact with dogs. Humans can rarely become intermediate hosts when they are infected by ingesting contaminated food, or by contact with infected animals (1). Cerebral hydatid cysts are rare, and comprise only 2-3% of all reported cases of hydatid cysts (2). They often become significantly larger in children.

Clinic symptoms may show different characteristics depending on their locations in the brain. Cardiac hydatid cysts are uncommon, accounting for about 0.5-2.0% of all cases (3), but their potential lethal risks have been shown clinically. The Medline database research have yielded only two cases of the heart and brain being affected without the involvement of any other organ to date (4,5).

## CASE REPORT

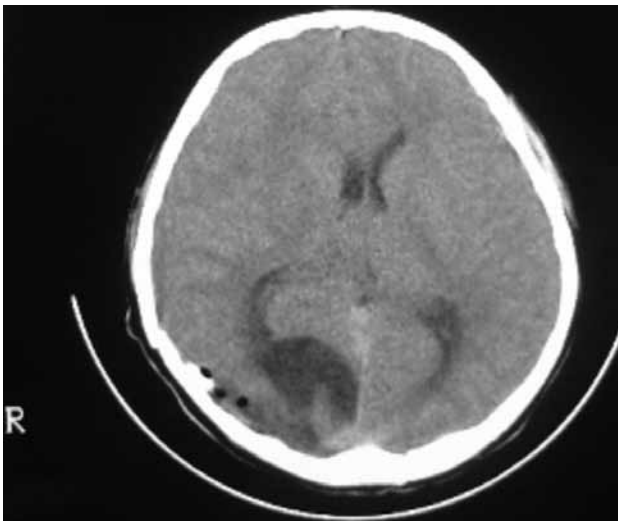
We present one pediatric case of multiple hydatid cyst in the brain and heart. The patient, a 12-year-old boy who presented with headache, vomiting, diplopia,



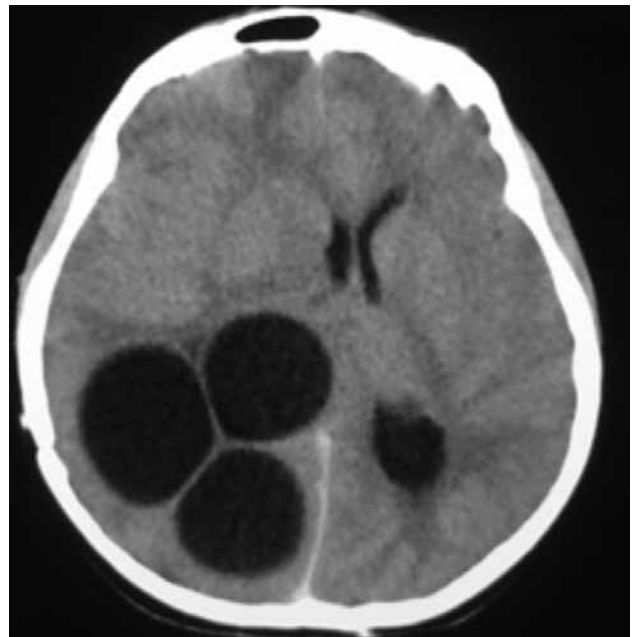**Figure 1a:** Preoperative T1-weighted MRI of coronal section showing hypointense (izointense with cerebrospinal fluid signal) multiple hydatid cysts.



**Figure 1c:** Cyst seen intact postoperatively.



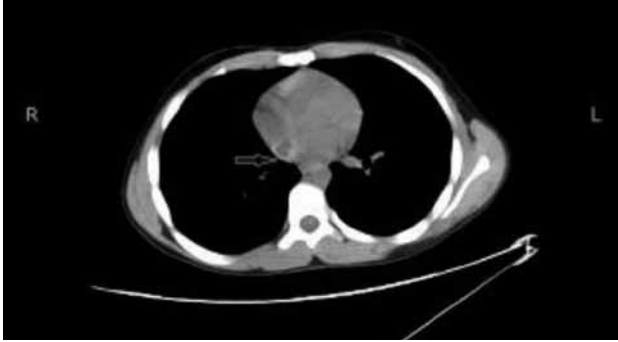**Figure 1b:** Postoperative Brain CT demonstrate cyst total removal.



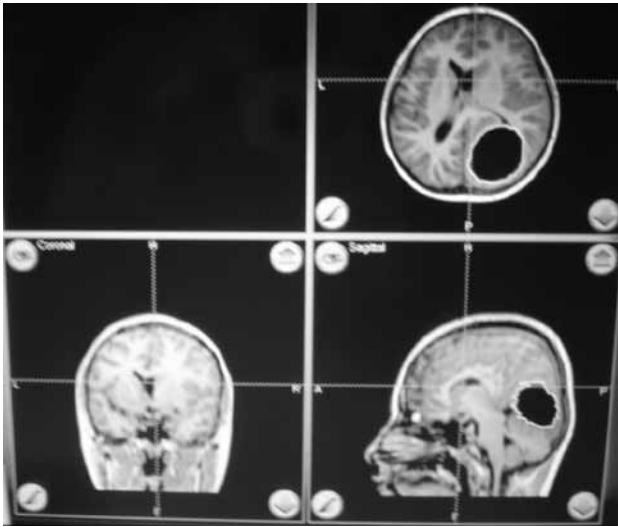
**Figure 2a:** After recurrence, multiple hydatid cyst seen in the same location on CT and craniotomy defect.

weakness in his left side and grand mal seizures for about 10 days. He was admitted to our neurosurgical department. On examination, he had signs of raised intracranial pressure with sleepiness and left hemiparesia. Funduscopic examination revealed papilledema.

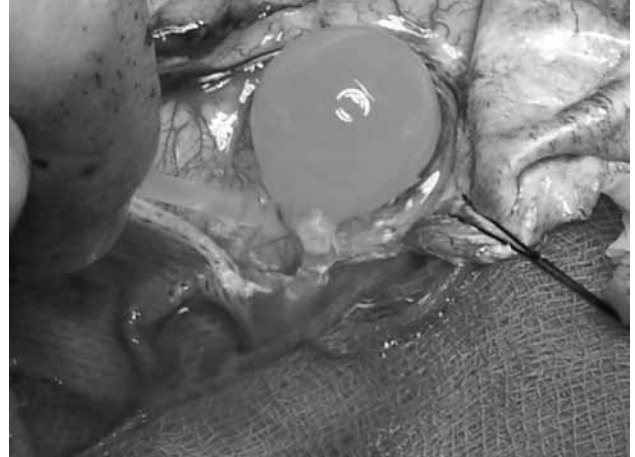Routine blood analyses and serologies were within normal limits. The patient had cranial operation from primary multiple hydatid cysts one year before (Figure 1a-b). The cysts were delivered without rupture at the first operation (Figure 1c). During his follow-up period, he had no symptom, but symptoms resulting from increased intracranial pressure had been seen for about 10 days. Therefore, CT was performed, which revealed in the same right parieto-occipital localization a multiple cystic lesion without rim enhancement or perifocal edema (Figure 2a). We investigated the first origin of the



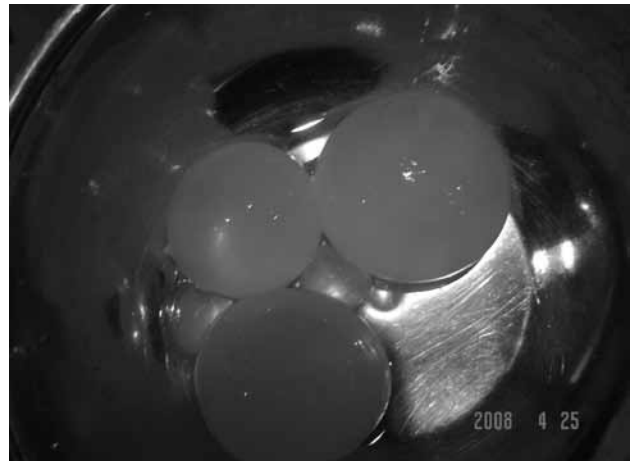
**Figure 2b:** Cardiac cyst seen in the left atrium by thorax CT (arrow).



**Figure 3a:** Neuronavigation used for intact delivery of cysts intraoperatively.



**Figure 3b:** The cysts delivered by the Dowling technique.



**Figure 3c:** Cyst delivered intact in the second operation by the Dowling technique. The intact cysts shown also postoperatively.

disease, patient's heart, lungs and liver through CT, abdominal USG and echocardiography. Before the initial surgical treatment, the first origin had not been found on the lungs, liver or heart. Patient's serologic tests were negative. Therefore, multiple brain lesions had been accepted as primary origin. After the recurrence of the disease in the same area, the first origin was investigated carefully. Patient's lungs and liver were found disease-free, but his heart was revealed as the first origin of hydatid cyst by thorax CT (Figure 2b). The Casoni and Weinberg tests were negative. The second operative approach was planned with neuronavigation (BrainLab Vector vision2, Munich, Germany) (Figure 3a).

Large parieto-occipital craniotomy was performed, and firstly a large cyst was removed by using the Dowling technique (6), and then other cysts were removed similarly by the Dowling technique (Figure 3b-c). The postoperative course was uneventful, and the patient showed a marked recovery in his neurological status.

Because of the hydatid cyst in the heart, 10-15 mg/kg of albendazole was regularly given three times day for 3 months, and the patient was referred to the cardiothoracic surgery department.

## DISCUSSION

Cerebral hydatid cysts are rare and include only 2-3% of all reported hydatid cysts (2). They constitute up to 3-4% of all intracranial space-occupying lesions (2,7). Cerebral hydatid cysts are usually single. However, primary multiple hydatid cysts have also been reported (8). Primary multiple cerebral hydatid cysts are extremely rare, and result from spontaneous, traumatic or surgical rupture of a solitary primary cyst, or as a consequence of a cyst ruptured elsewhere, and embolization of hydatid cysts to the brain. In addition, it is believed that multiple cysts may also grow after the rupture of a cyst located in the left cardiac cavity or great arterial vessels (2). The patient in our case had been operated on successfully. The patient's hydatid cysts were removed unruptured by neuronavigation guided surgery. Ten months later, the cranial disease repeated in the same localization, with the primary origin of the disease found in the left cardiac atrium.

Patients with cerebral hydatid cysts may have hydatid cysts also in other organs. Less than 20% of patients with intracranial hydatidosis demonstrate other organ involvement (1). In his series, Ciurea et al. (9) reported 29.6% hydatid disease in multiple organs. Cardiac hydatid cyst is rare, accounting for only 0.5-2.0% of cases (3). On the other hand, cardiac echinococcosis with negative serologies was reported in two cases. Salehi and Soleimani (10) reported that one case had been operated 10 years before for hydatid cyst of the brain.

The Medline database research yielded only two cases of the heart and brain being affected without other organ involvement (4,5).

Most common symptoms of centrally placed cases, depending on the size of the cyst, are headache, increasing intracranial pressure, vomiting, and findings of extra pyramidal system signs (1). In this case, the related symptoms were headache, left hemiparesia, and vomiting.

Cardiac symptoms are dyspnea, chest pain, palpitation, or anaphylactic reaction. Cardiac disease may run silently. However, its clinical presentation may vary (4,10).

Both CT and MRI demonstrate cerebral hydatid

cysts adequately. MRI seems to be used more widely for the diagnosis and surgical planning in cerebral hydatid disease. Oedema and contrast enhancement are usually absent in untreated or uncomplicated cases. On MRI, the signal intensity of the cyst is isointense with cerebrospinal fluid on all pulse sequences. Variable amounts of septa could be observed. MRI demonstrates the hydatid cyst as a spherical, thin-walled structure containing fluid with CSF imaging characters (9).

In children, clinical manifestations of cerebral hydatid cysts are primarily those related to increased intracranial pressure. Headache and vomiting were the most common presenting symptoms in patients, as reported by literature. Other symptoms such as hemiparesia, seizures, visual field alteration, and gait disorders may vary with the location of the cyst (1,6). This case presented with raised intracranial pressure symptoms, and he had no cardiac complaints and signs.

Hydatid disease is generally a severe disease, with over 90 % mortality in untreated patients. The treatment of hydatid cyst is surgical. It should be removed without rupture. Oral 40-50 mg/kg/day mebendazole for 1-3 month, or 10-15 mg/kg/day albendazole for a month are also suggested pre- and post-operatively (1,2,6,9).

The recurrence rate in series of Ersahin et al. (2) was only 1.4%. In other series, the recurrence rate was 40.7% due to cyst rupture at surgery (9). In our case of hydatid cyst, recurrence, which was owing to the cardiac focus of the cyst, was determined in the same region in the first year of the treatment.

## CONCLUSION










Such cysts are readily ruptured during the operation, and recurrence is the rule. Avoiding this risk, a cortical incision must be equal and appropriate to the cyst diameter. However, larger cortical incision may increase morbidity. To avoid such a result, we have used neuronavigation system in surgical planning and approach. Thus, we have been able to achieve minimal invasive surgery in such gigantic cerebral hydatid cysts.

Hydatid cyst is still a serious disease in Turkey. Proper treatment is absolutely necessary, and these patients should be observed for a long time, regarding

the recurrences and complications. In addition, if the diagnosis of primary multiple hydatid cyst has been made previously, this diagnosis should be checked. Even if the primary origin has not been revealed, and the cyst has not been ruptured in the operation, the

illness may be hidden in a different location. Therefore, the investigation of other organ diseases for the primary focus should be considered. Researchers should not hurry to reach a conclusion for intracranial primary multiple hydatid cyst, as was in our case.

## REFERENCES

1. Turgut M. Intracranial hydatidosis in Turkey: Its clinical presentation, diagnostic studies surgical management, and outcome. A review of 276 cases. *Neurosurg Rev* 2001; 24:200-208.  

2. Ersahin Y, Mutluer S, Guzelbag E. Intracranial hydatid cysts in children. *Neurosurgery* 1993; 33:219-225.  

3. Maden O, Atak R, Yetgin E. An unusual primary left ventricular hydatid cyst complicated by cardiac tamponade. *Angiology* 2002; 53:487-491.  

4. Aleksic-Shihabi A, Vidolin EP. Cystic echinococcosis of the heart and brain: a case report. *Acta Med Okayama*. 2008; 62: 341-344.  

5. Bükte Y, Kemaloglu S, Nazaroglu H, Ozkan U, Ceviz A, Simsek M. Cerebral hydatid disease: CT and MR imaging findings. *Swiss Med Wkly*. 2004; 134:459-467.  

6. Carrea R, Dowling E Jr, Guevara JA. Surgical treatment of hydatid cysts of the central nervous system in pediatric age (Dowling's technique). *Childs Brain* 1975; 1:4-21.  

7. Tuzun M, Altinors N, Arda IS, Hekimoglu B. Cerebral hydatid CT and MR findings. *Clin Imaging* 2002; 26: 353-357.  

8. Per H, Kumandaş S, Gümüş H, Kurtsoy A. Primary soliter and multiple intracranial cyst hydatid disease: report of five cases. *Brain Dev* 2009; 31: 228-233.  

9. Ciurea AV, Vasilescu G, Nuteanu L, Carp N. Cerebral hydatid cyst in children. Experience of 27 cases. *Childs Nerv Syst* 1995; 11:679-685.  

10. Salehi M, Soleimani A. Cardiac echinococcosis with negative serologies: a report of two cases. *Heart Lung Circ*. 2009; 18:59-61.  
